


DIRI

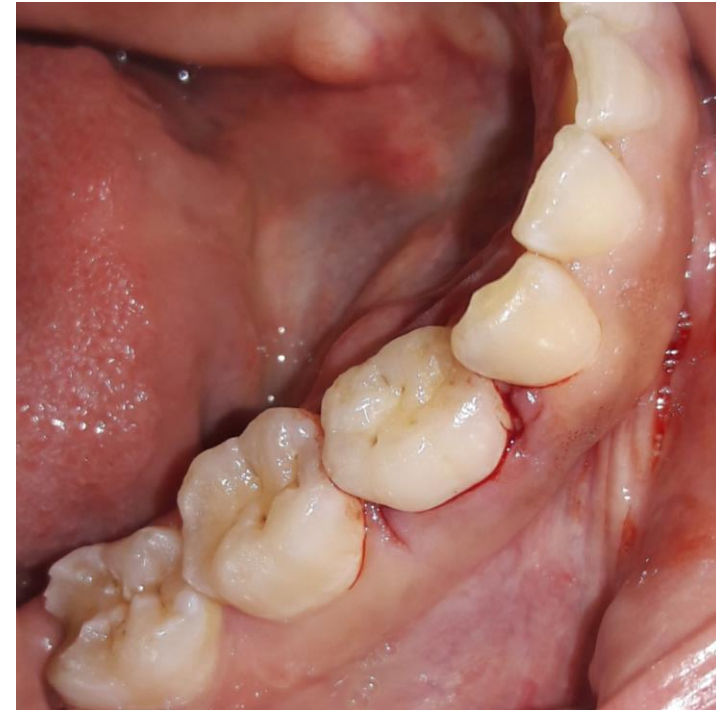


Dente 84 com mobilidade.

SelfConnect Concept


Caso Clínico:

- Paciente 23 anos de idade
- Exodontia do dente decíduo
- Colocação de implante e Pilar SelfConnect
- Instalação de Cilindro Cicatrizador Anatômico.



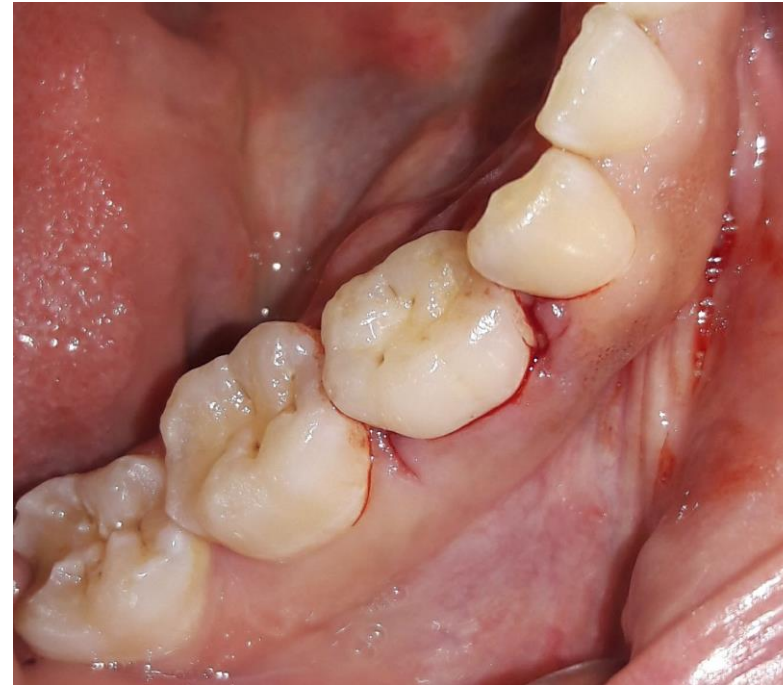
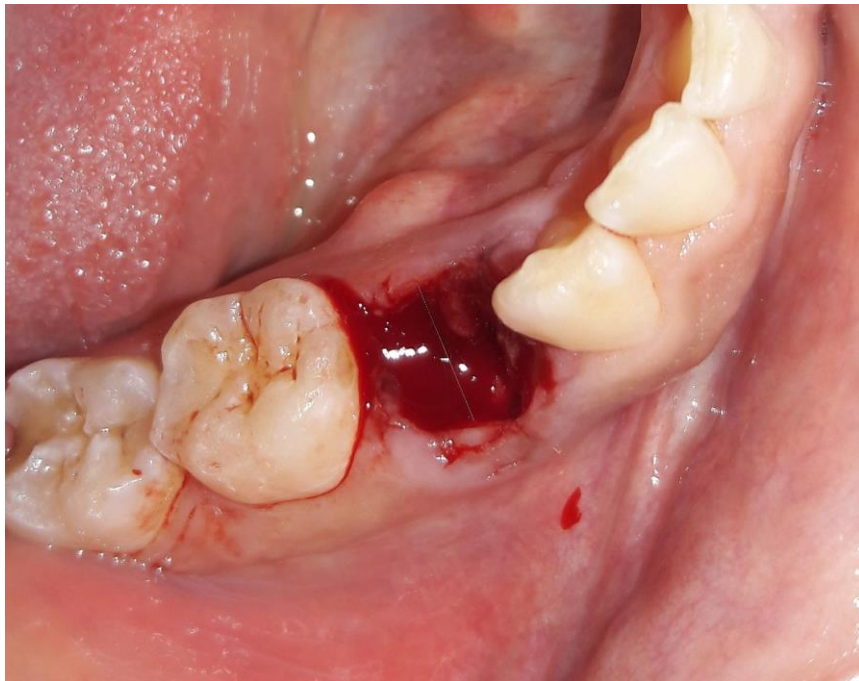
Dr. Wail

DIRI



Dente 84 com mobilidade.

SelfConnect Concept



Exodontia simples.



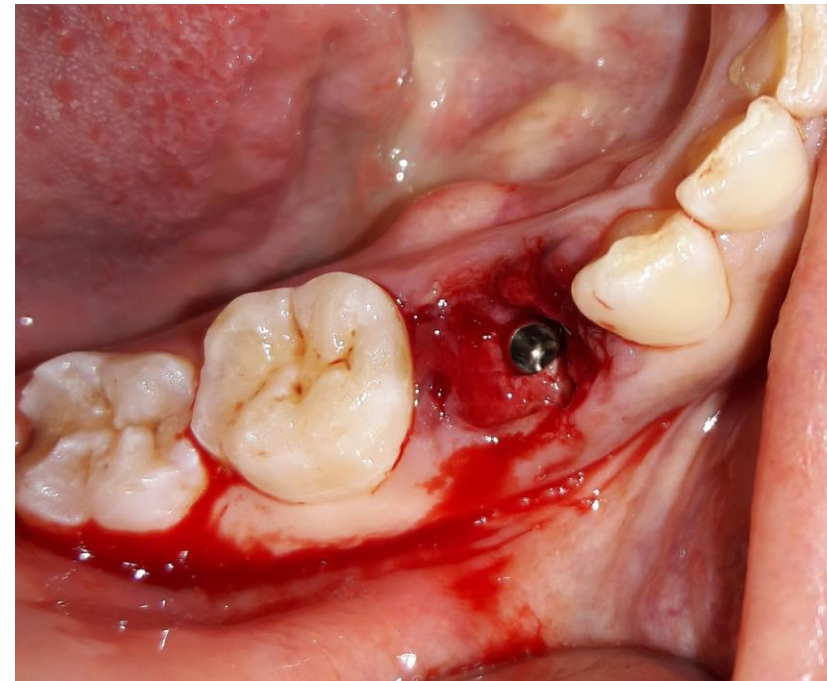
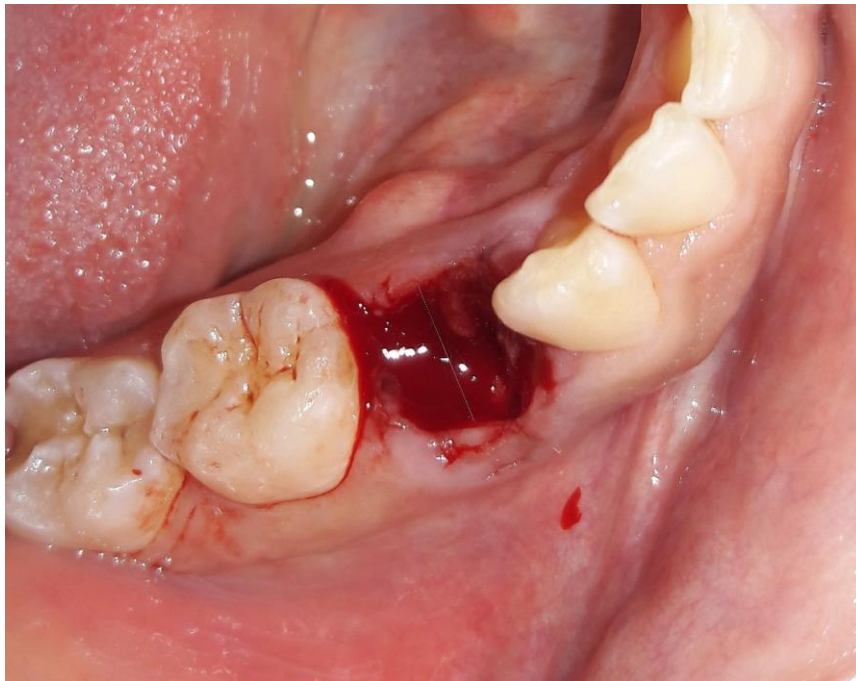
Dr. Wail

DIRI



Colocação de implante Titamax CM
(Neodent-Curitiba).

SelfConnect Concept



Implante colocado.



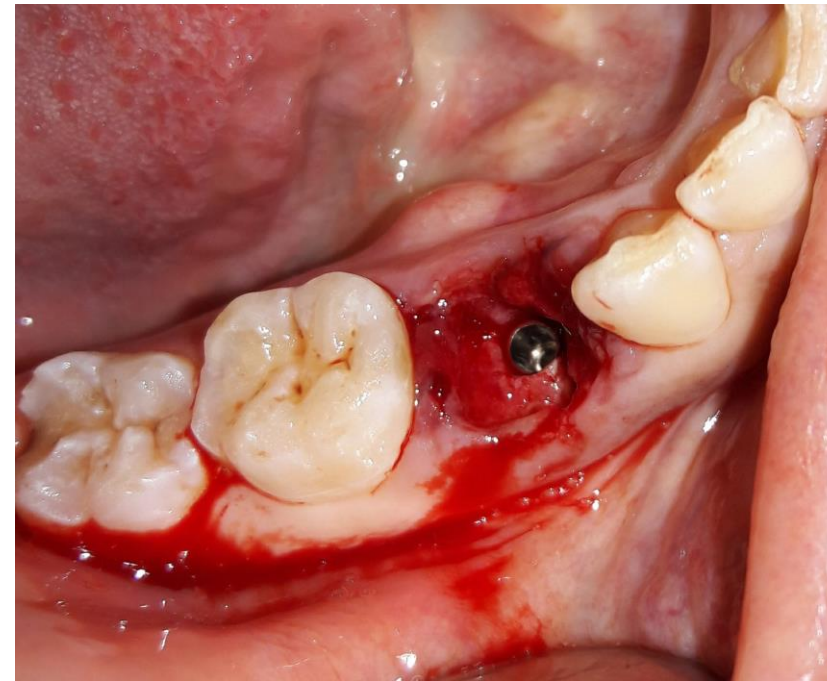
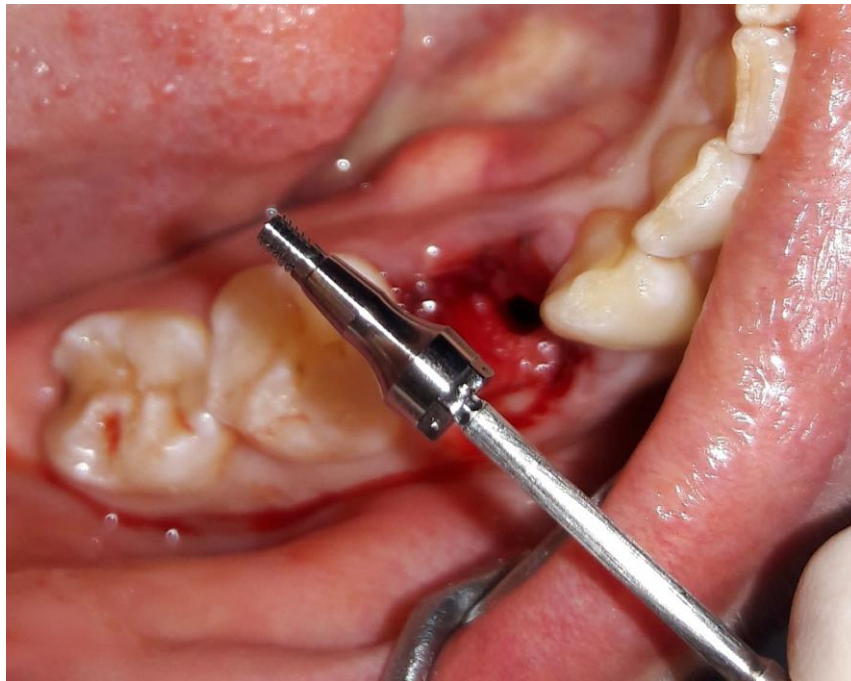
Dr. Wail

DIRI



O Pilar SelfConnect Wide, altura gengival 2,5 foi escolhido para esse caso (DIRI-Fortaleza).

SelfConnect Concept




Pilar SelfConnect Wide escolhido.



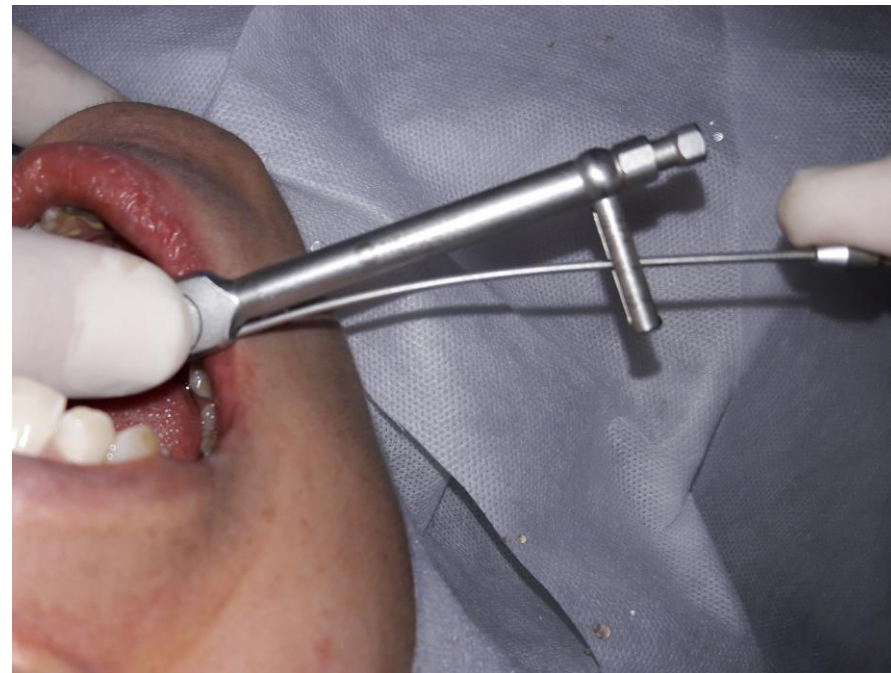
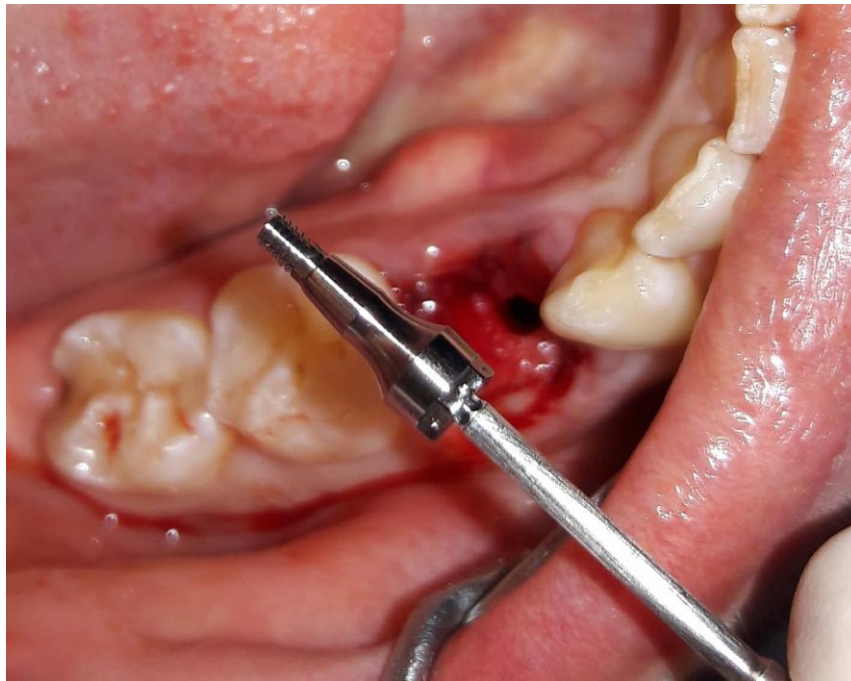
Dr. Wail

DIRI



Instalação do Pilar SelfConnect, com auxílio de chave 1,2 e catraca, torque de instalação é de 32N.

SelfConnect Concept



Torque de instalação final.



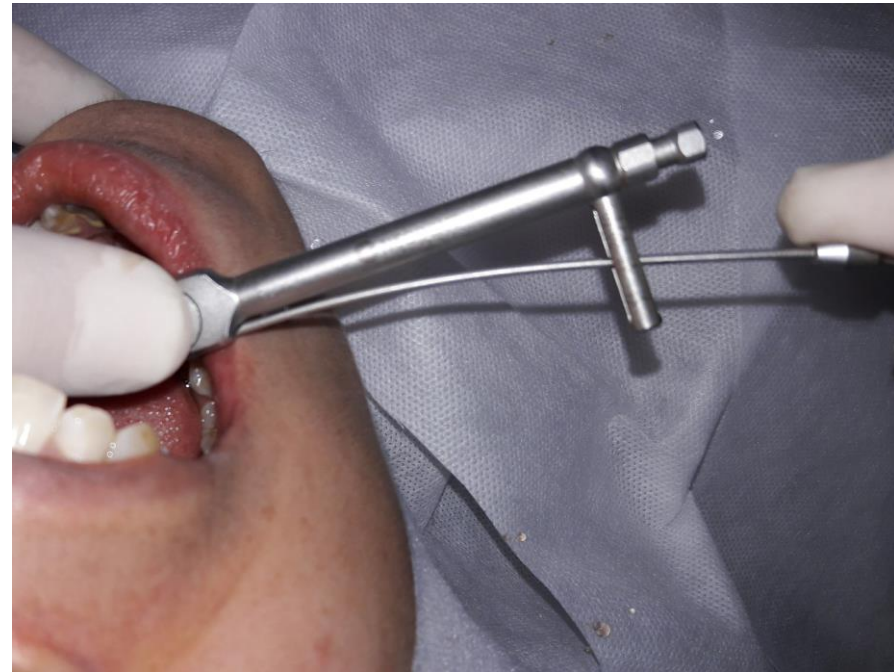
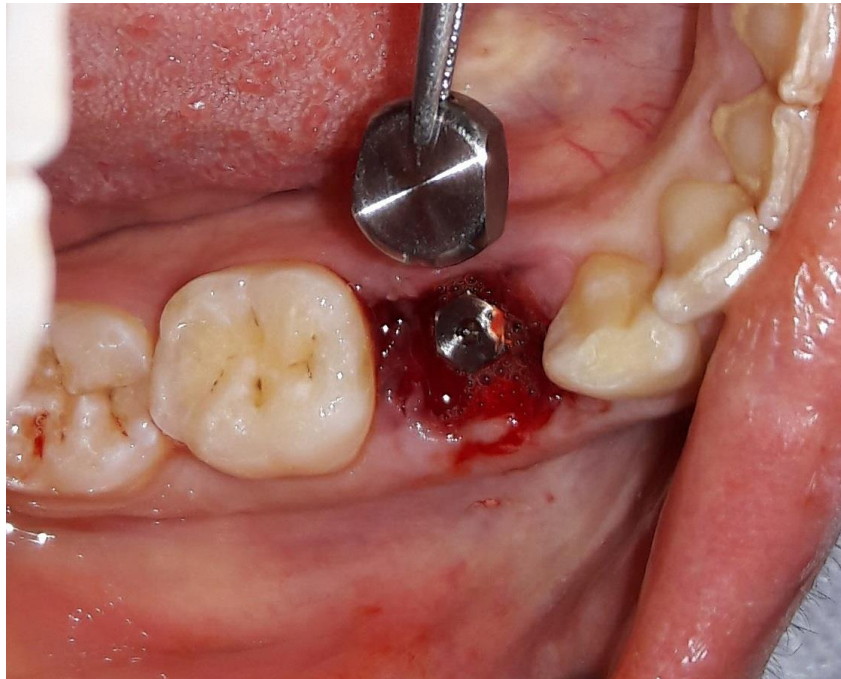
Dr. Wail

DIRI



Escolha do tamanho correto do Cilindro Cicatrizador Anatômico é importante para garantir selamento gengival adequado.

SelfConnect Concept



Prova do Cilindro Cicatrizador.



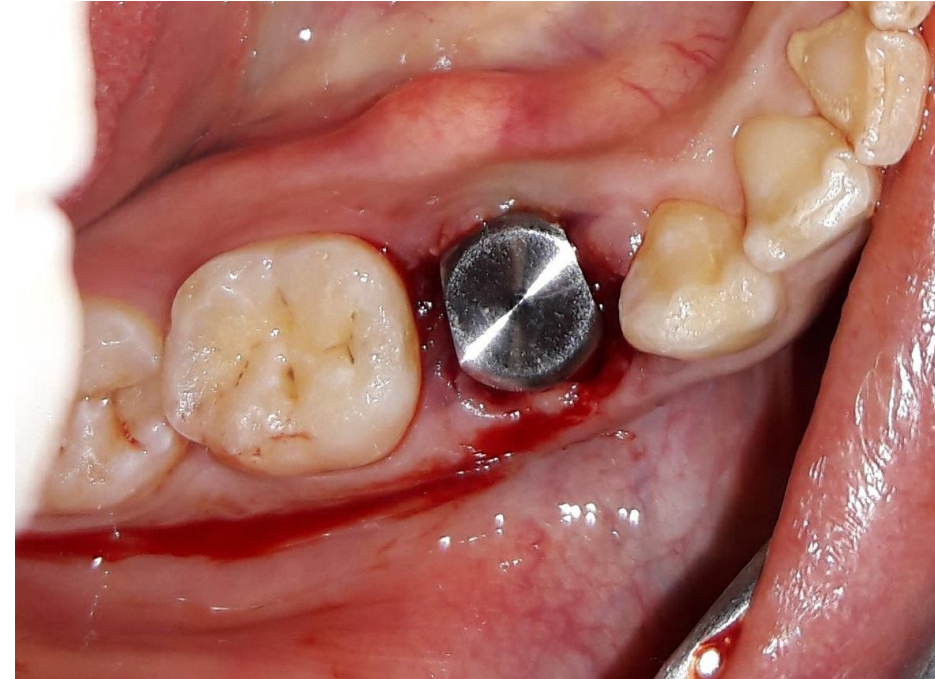
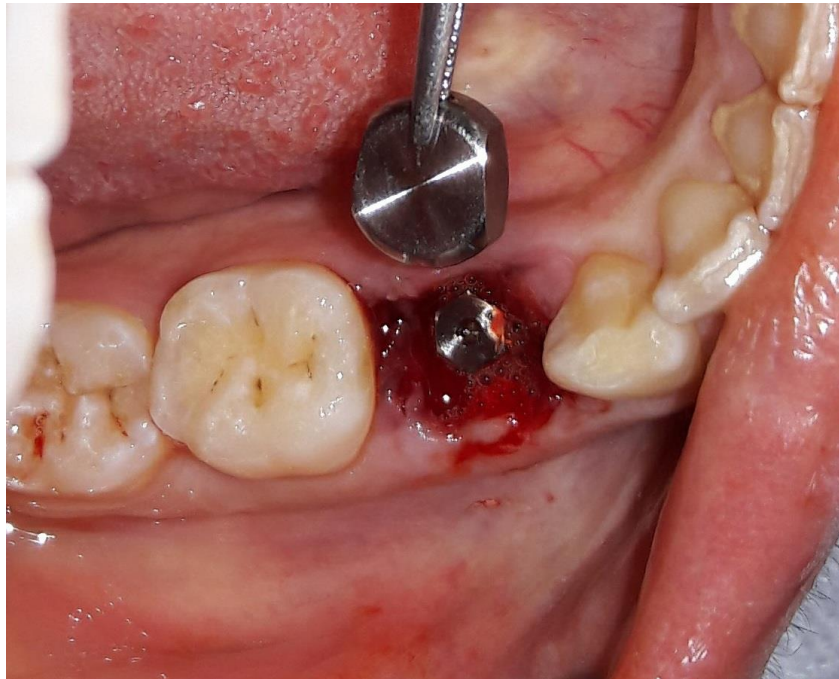
Dr. Wail

DIRI



A fixação inicial do Cilindro Cicatrizador acontece com preção digital, essa fixação deve ser aumentada com leve impacto ou com auxilio da mordida do paciente sobre um cabo de plástico ou de madeira.

SelfConnect Concept




Prova do Cilindro Cicatrizador.



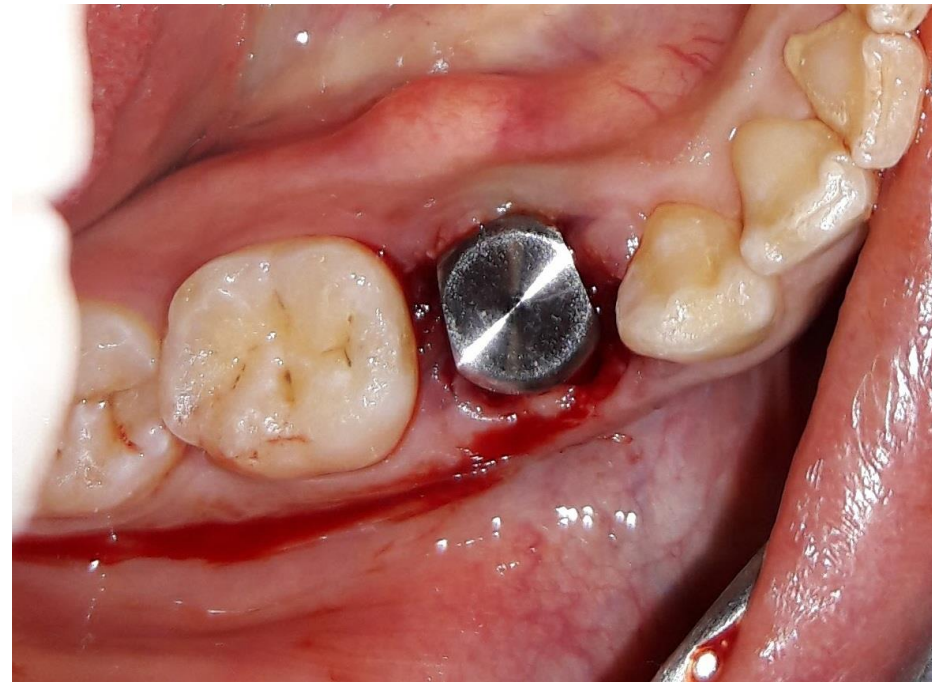
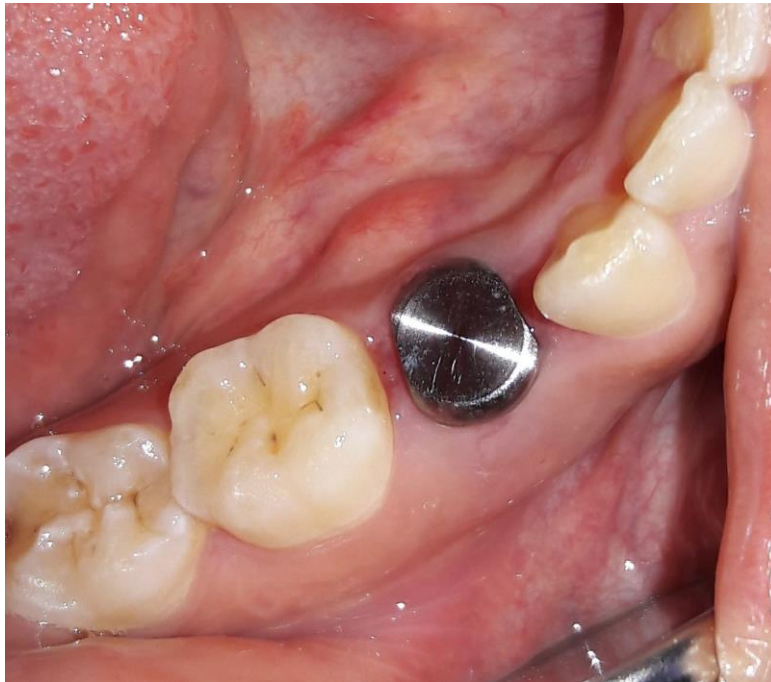Dr. Wail

DIRI



A fixação friccional é biológica, garante resposta gengival rápida e adequada.

SelfConnect Concept



Aspecto clinico 04 dias depois.



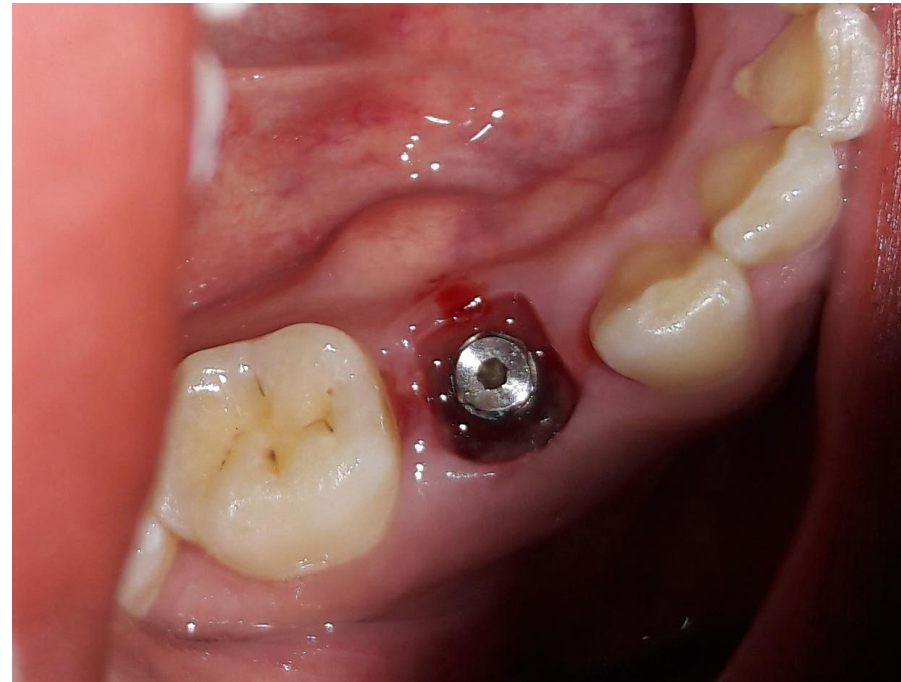Dr. Wail

DIRI



A fixação friccional é biológica, garante resposta gengival rápida e adequada.

SelfConnect Concept




Aspecto clinico 04 dias depois.

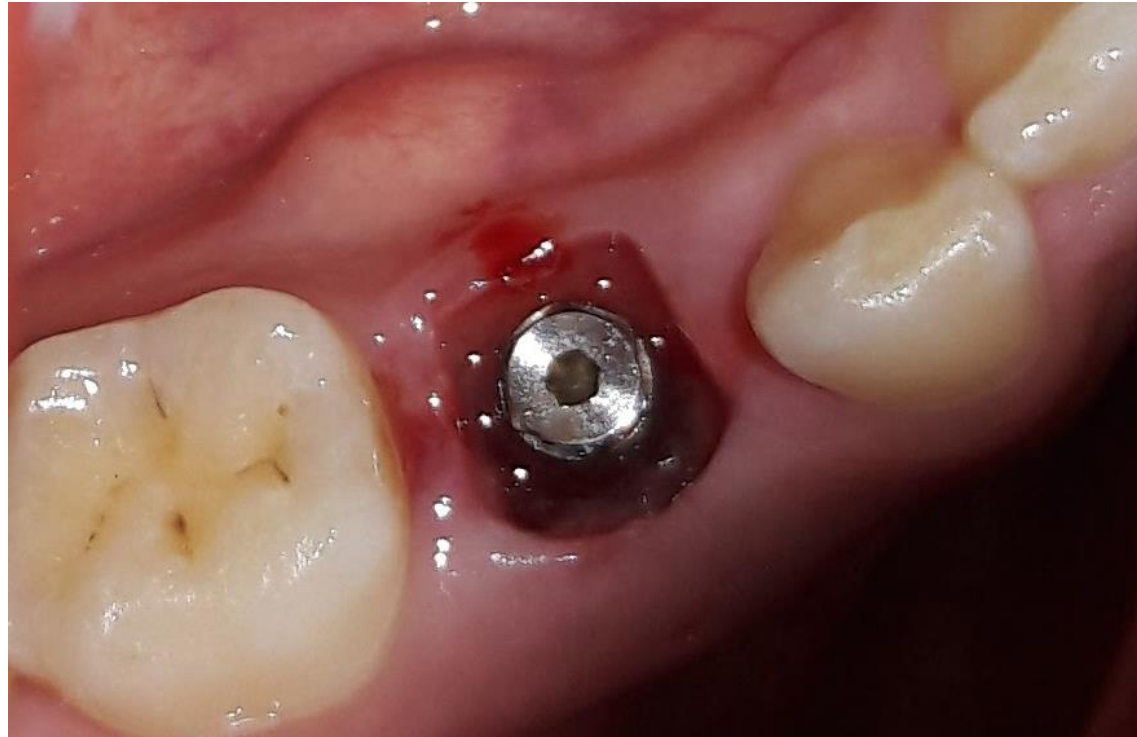

Dr. Wail

DIRI



SelfConnect Concept



Dr. Wail